Doctor : Dr. Rob Veis
Patient : Michael Smith Age : 11 years, 8 months Sex : Male Date : 6/7/2006 Timepoint : Initial

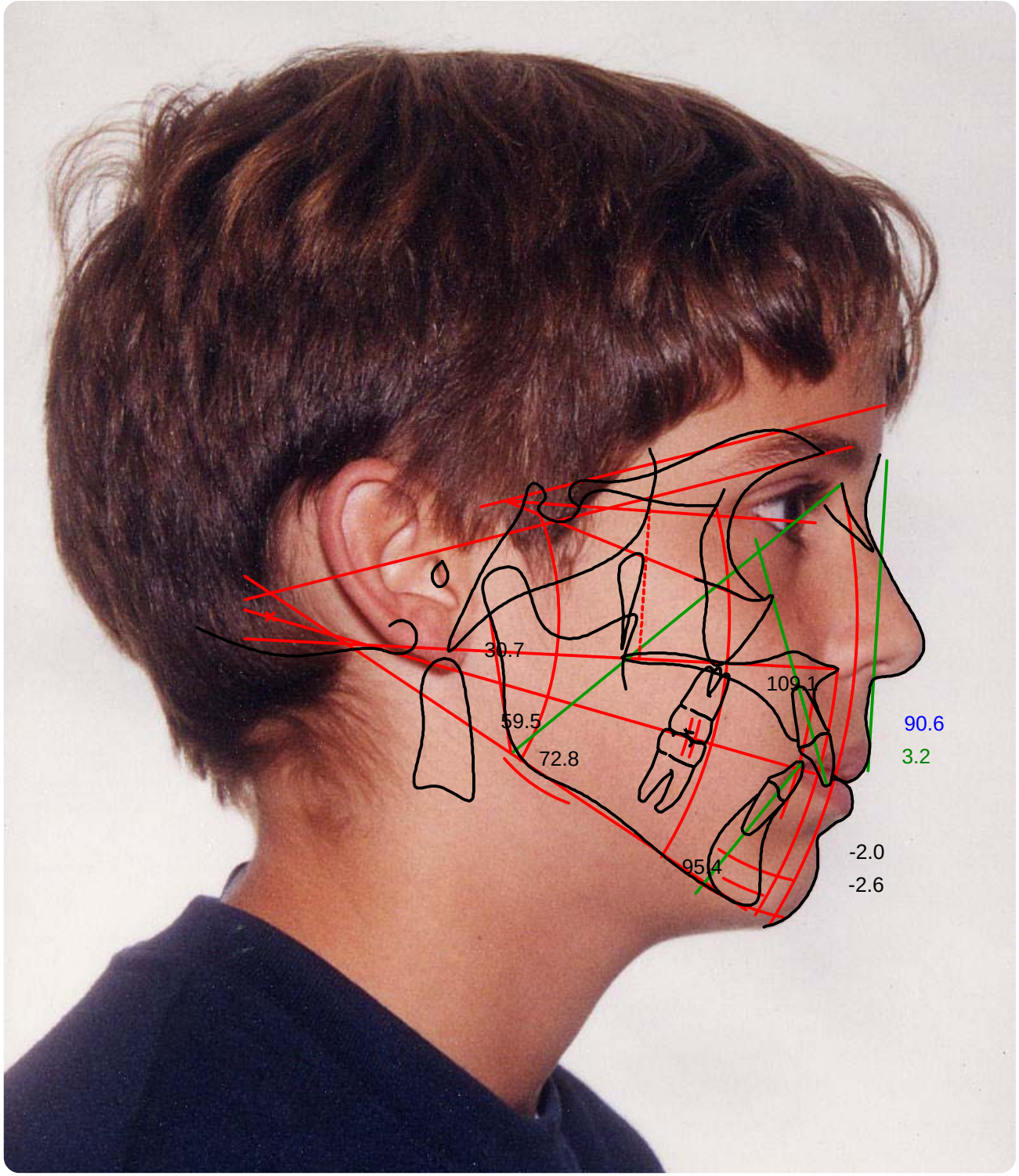

Research has shown that superimposing a cephalometric tracing over a patient's image can only provide limited diagnostic value. We highly recommend that you capture radiographic images and take soft tissue images in such a way as to minimize discrepancies between them in orientation and view angle. Keep in mind, that due to the radiograph machine design and the distortions of the camera's optical lens, the two images will never match exactly.